


Example

		Case Report Form		
		Julie Avalos		pg 1 of 5
Case Log#:10	Date: 9/13/16	Species: canine	Sex: M	Age: 2 yrs
Weight (kg or grams): 30.8kg	ASA status (for anesthesia cases): II	Nursing or Study Aim: management of surgical complications (incision dehiscence) and development of plan to prevent further complications		
Name or ID: Carl (15D10)		Research Variables: type 2 diabetes study		

Carl is a 2yr old intact male, purpose-bred large hound. He is assigned to the Insulin Clearance in the Development of Insulin Resistance study. He underwent his first laparotomy for placement of a portal vein vascular access port (VAP), baseline liver biopsy, visceral fat biopsy and medial thigh muscle biopsy on 11/10/15. Recovery was uneventful and as expected for the procedure.

He was scheduled for a second laparotomy to obtain liver, visceral fat and muscle biopsies and to assess patency of portal vein VAP on 9/13/16, as approved in the IACUC protocol. Study approved procedures leading up to the second laparotomy (Hyperinsulinemic Clamp and Intravenous Glucose Tolerance Tests) showed an average fasting blood glucose level of 100.62mg/dl. At my pre-op examination he presented as BAR, hydration normal by skin turgor, 30.8kg, BCS 5/9. Vitals were assessed: HR 82 beats per minute, respiration 20 breaths per minute, rectal temp 99.1F, mm pink and moist, CRT 1 second. ASA II. Acepromazine was administered at 0.25mg/kg SQ and injectable carprofen was given at 4mg/kg SQ. Propofol and oxymorphone were calculated and drawn up. I obtained oxymorphone from the double lock box and the dose was logged in CII log. The OR was staged with sterile surgical packs, gowns and gloves. I turned on the radiant heating pad and allowed it to warm while the cryotank for biopsy sample flash freezing was filled with liquid nitrogen. Anesthesia machine hoses were checked/attached, vaporizer filled, and CO2 absorber granules changed. During the rebreathing system leak check I detected a leak. I went back over the system, double checking all connections and discovered a faulty o-ring on the delivery flutter valve, thus causing the slow leak I had detected. I replaced the o-ring and repeated the leak test successfully. The suction system was connected to central vacuum and verified on line.

Carl was taken to the prep room for induction ~30 minutes after acepromazine administration. I placed a 22ga x 1" peripheral IV catheter in the right cephalic vein. Propofol 3.7mg/kg was administered slow IV to effect in order to intubate. Prior to intubation an esophageal temperature line was inserted to monitor core temperature throughout the procedure. I placed a 9mm cuffed endotracheal tube and secured it with gauze tie. Proper location was verified by auscultating lung sounds bilaterally. Isoflurane was initiated at 3%, driven by 100% O2 at 1 LPM during surgical prep. Hair was clipped from the ventral abdomen to provide wide margins for a full laparotomy, along with the right groin for muscle biopsy and a patch was clipped along the dorso-lumbar area for the cautery grounding pad. The loose hair was vacuumed and a cursory scrub using 2% chlorhexidine scrub followed by saline rinse was performed. Following initial surgical clip/prep the dog was moved into the OR and placed into dorsal recumbency on the V-table and the front limbs and left hind limb were secured with ties, leaving the right hind in a relaxed position to facilitate access to the inner thigh muscle for biopsy. WAG was scavenged using the house exhaust run through a scavenge interface valve. I verified the WAG system as functional by observing the breathing movement of the reservoir bag. Mechanical ventilation was maintained via a Hallowell 2002IE ventilator. A blood pressure cuff was attached to the right forearm, the pulse oximeter sensor to the tongue, the capnograph end-tidal CO2 sensor to the breathing circuit, a three lead EKG attached, and the esophageal temp probe plugged into the V-Med receiver box to obtain vitals. I plugged the grounding patch into the cautery unit and the machine indicated proper grounding had occurred with an audible alert. Vitals (NIBP, Temp, HR, SpO2, EtCO2) along with IPPV breaths per minute were recorded every 5 minutes during the procedure on the anesthesia log that I later scanned and uploaded into Carl's GLP-compliant electronic medical record. Palpebral reflex and jaw tone were assessed as negative. Isoflurane was decreased to 2% for the duration of the procedure. Our established parameter guidelines of 8-15 breaths per minute, tidal volume 10-20mL/kg, ventilator pressure 10-14cm H2O and EtCO2 35-45mm Hg were used to adjust anesthesia and respiration rate as needed throughout the procedure. I started Lactated Ringers solution at 5mL/kg/hr, for the first hour, then decrease to 2.5mL/kg/hr. Oxymorphone was administered 0.065mg/kg slow IV prior to first incision. I instructed that 50mg of

bupivacaine HCl & epinephrine be injected as a local block at the midline abdominal incision site 5 minutes prior to incision. Liver biopsy sections were cut by surgeon and placed onto pieces of pre-autoclaved aluminum foil that were then folded to secure the samples and placed into the liquid nitrogen for flash freezing. During the procedure, it was determined that the portal vein catheter had slipped out and replacement was not possible due to excessive scarring. The catheter was tied off, removed from the abdomen cavity and secured to muscle wall. About 2 hours into the procedure I noticed that the EtCO₂ slowly increased above 45mmHg and the respiration rate sensor was reading lower than the ventilators pre-set respiration rate. With no other physiological indications and no mechanical failures to explain the increase I determined it was due to a saturated heat moisture exchange filter. Once the filter was replaced the reading returned to expected levels. The surgical procedure lasted nearly 3 hours. At the end of the procedure I discontinued the isoflurane but the dog was maintained on the ventilator while he was repositioned and prepared for transport. Prior to transport mechanical ventilation was discontinued and he was allowed to spontaneously breath. His breaths were shallow in the beginning and his O₂ saturation rate began to fall. I gave him several breaths with the ambu bag which increased the O₂ saturation quickly, he then began to breath more deeply and was able to maintain acceptable O₂ saturation on his own. At that point he was transported to recovery.

Carl arrived in the recovery room at 12:45pm and I placed him into lateral recumbency on the radiant heating pad. Initial vitals were taken: HR 116bpm, rectal temp 99.1F, respiration 16 breaths per min, jaw tone/swallow reflex neg/neg. I gently cleaned the incisions with dilute chlorhexidine solution and allowed them to dry before applying triple antibiotic ointment (TAO) and covering with gauze square and tegaderm bandage. Dog was extubated at 1pm after presence of positive jaw tone and swallow reflex. Buprenorphine 0.6mg IM was administered and dog was allowed to rest. By 3:00pm Carl had recovered well and was up and exploring the pen. I removed the heating pad and IV catheter and placed a "bite not" collar (neck collar) to prevent access to incisions. Mild serous discharge was observed on the ventral abdominal

bandage, but was expected for this procedure. He was left in the recovery pen overnight NPO and reassessed the following am. [Dosing frequency of buprenorphine?](#)

In the AM, Carl presented BAR with moderate serous discharge on the abdominal bandage. I removed the bandage and cleaned the incision with diluted chlorhexidine solution, applied TAO and the tegaderm/gauze sponge bandage was replaced. Administered 0.6mg buprenorphine SQ and 125mg carprofen SQ. He was offered food and water, but his appetite was poor. The treatment plan was to keep him housed outside of the normal population for ~ 7days to minimize activity and keep incisions clean to aid in healing. His appetite returned to normal within a few days and he adjusted to the recovery room housing well. He was allowed supervised exercise twice daily to remain compliant with regulations and to give him additional positive contact. I provided either an Havaball or a Kong for enrichment on a rotation as well as increased human contact from veterinary and laboratory staff. Although he was individually housed during most of this stay in recovery, he did not exhibit any inappropriate behaviors or stereotypies to indicate stress from the lack of socialization with other dogs. A light gauze sponge/tegaderm bandage was maintained over abdominal incision to keep the area clean and the neck collar remained.

At bandage change on 9/19, I observed that the ventral abdominal skin incision dehiscd ~3-4 inches along the cranial aspect; muscle layers were intact and healing as expected. Continued sero-sanguinous discharge was impacting healing. The area was cleansed with dilute chlorhexidine solution and skin staples were placed to appose the margins and promote healing by secondary intention. Dog was normothermic. TAO was applied to the area and cephalexin was started at 500mg PO BID x 7 days. The incision was left uncovered to better monitor healing and was gently cleansed followed by application of TAO daily as previously described. The neck collar was left in place.

On 9/27, I instructed that Carl be returned to regular housing room and allowed to resume normal exercise. The ventral abdominal incision continued to granulate in slowly. Staples remain in place.

On 10/3, At examination I found the incision had contracted to ~2cm in diameter with a fresh granulation bed filling in. Skin staples were removed. Daily cleansing and TAO application were continued until completely healed.

10/10/17: Incision completely healed, collar removed.

Scar tissue present at the midline abdominal incision from the first laparotomy and the high activity level (commonly seen with intact male hounds) were factors in the delayed healing. As a result of this case, we augmented the suture technique and pattern used for the abdominal closure and the post-op care of dogs on this study, in particular for the second laparotomy procedure.

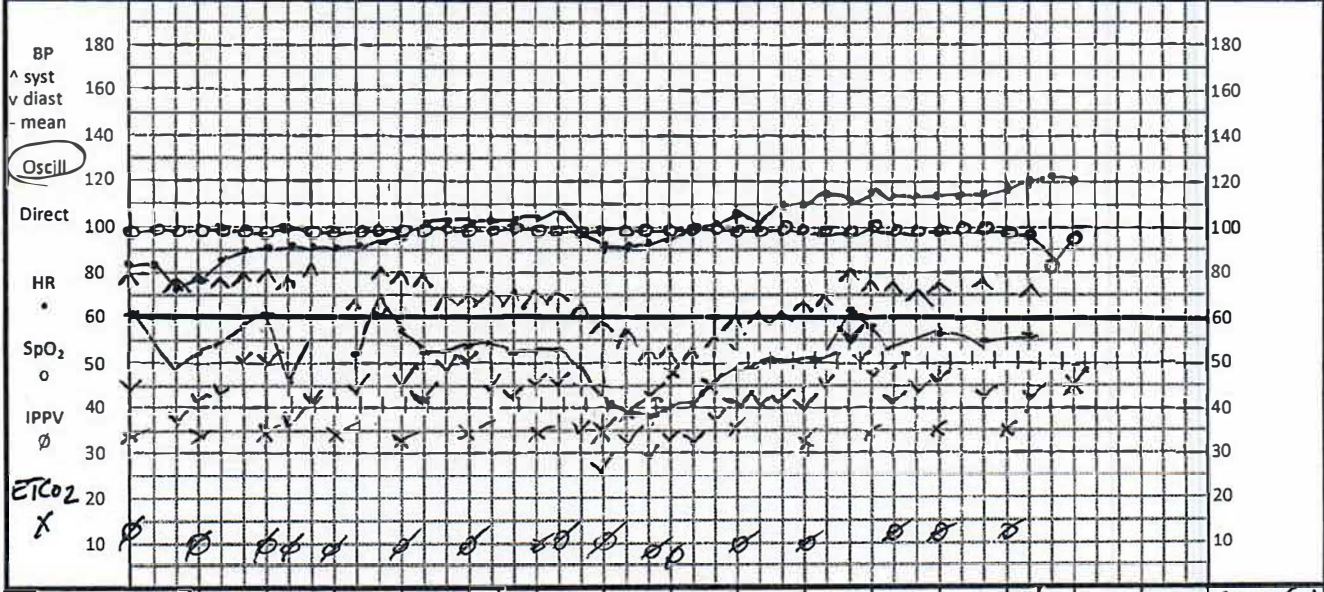

Department of Comparative Medicine
Record of Anesthesia

Date: 9/13/16 Primary Investigator: _____
 Species: Canine Breed: Hound IACUC#: _____
 Animal ID#: 15010 Procedure: Biopsies: liver, visceral fat, muscle
 Weight 30.8 kg Temp 99.1 F HR 82 RR 20 MM color pink/moist CRT 1 sec.
 Room # URS Endotracheal Intubation Size 9 mm Problems N/A

Pre-Anesthetic Drugs				Pre-Induction Status		Anesthetic Induction			
Drug	Dose	Route	Time	Sedation	Resistance	Drug	Dose	Route	Time
<u>Acepromazine</u>	<u>8mg SA</u>	<u>SA</u>	<u>8:15a</u>	<input type="checkbox"/>	<input checked="" type="checkbox"/> None	<u>Propofol</u>	<u>115mg</u>	<u>IV</u>	<u>8:45a</u>
<u>Rimadyl</u>	<u>125mg SA</u>	<u>SA</u>	<u>8:15a</u>	<input type="checkbox"/>	<input type="checkbox"/> Slight				
				<input type="checkbox"/>	<input type="checkbox"/> Moderate				
				<input type="checkbox"/>	<input type="checkbox"/> Severe				

Time	9:10	9:25	9:40	9:55	10:10	10:25	10:40	10:55	11:10	11:25	11:40	11:55	12:10	12:25	12:40	Total Injectables
Agents	0	15	30	45	0	15	30	45	0	15	30	45	0	15	30	45
O ₂ /L/min	1															
ISO %	3	2											1	2	1.5	



F	URS 150ml/hr	75ml/hr														318.75ml
I																
U																
d																

Body Position VD
 Temp Es Re 98.7 98.6 98.6 98.6 98.8 99.1 99.1 99.1 99.1 99.1 99.1 99.1 99.1 99.1

Start Anesthesia 9:00am End Anesthesia 12:25pm Extubation 1:00pm

Comments: Bupivacaine 50mg @ midline abdominal incision site @ 9:15am
Dexamorphone 2mg IV @ 9:30. Incision made @ 9:38am. VAP catheter found
to be pulled out of portal vein. Liver biopsies obtained @ 10:10am. Replacement
of portal vein catheter not possible due to scar tissue. Catheter line was cut back,
held off & sutured to exterior muscle wall. Midline incision closure
complete @ 12:20pm

Complications: Yes No Explain above or on back of form
 Anesthetist Signature Julie Avalos
 Print Name Julie Avalos